



Distraction Osteogenesis of the Mandible Followed by Lefort Osteotomy to Address Hemifacial Microsomia in an Adult Patient

Ivory JW¹, Jenzer AC^{2,*} and De Latour F³

¹Program Director, Department of Oral and Maxillofacial Surgery, Eisenhower Army Medical Center, USA

²Staff Surgeon, Department of Oral and Maxillofacial Surgery, Eisenhower Army Medical Center, USA

³Staff Surgeon, Department of Oral and Maxillofacial Surgery, William Beaumont Army Medical Center, USA

*Corresponding author: Jenzer AC, Staff Surgeon, Department of Oral and Maxillofacial Surgery, Eisenhower Army Medical Center, USA; Tel: 706-787-2648; E-mail: Andrew.c.jenzer.mil@mail.mil

Abstract

A healthy, active duty soldier was evaluated for significant facial asymmetry and diagnosed with right hemifacial microsomia. After a full evaluation and review of treatment options, he underwent distraction osteogenesis of the right mandible followed by orthognathic surgery. Distraction osteogenesis is an excellent technique that should be part of the armamentarium of any surgeon treating complex craniofacial deformities. This cases reviews distraction osteogenesis in the context of this case and treatment of an adult patient.

Keywords: Distraction osteogenesis; Mandible; Condyle; Hemifacial microsomia; Craniofacial deformities

Case Report

An active duty soldier, a 21-year-old male, was evaluated in the summer of 2017 for significant facial asymmetry. He was referred by his orthodontist for surgical treatment evaluation and planning. The patient has an unremarkable medical history with no surgeries, medications, allergies, or tobacco use. His chief complaint was “I am interested in having my bite corrected with braces and I have some pain and noises in my jaw joint.”

The patient’s physical exam revealed a significant cant of the dentition due to left mandibular condylar and ramus hypoplasia with associated facial asymmetry (Figure 1). His facial fifths, besides the obvious mandibular asymmetry, were otherwise equal, he displayed 2mm of maxillary tooth show in repose with maxillary midline coincident with the mid-sagittal plane, with 5mm of maxillary tooth show in animation. His mandibular midline was 3mm to the right of the mid-sagittal plane. He displayed balanced animation (Figure 2) with full buccal corridors and a noticeable cant. From a lateral perspective, he demonstrated

a straight facial profile with equal facial thirds, with associated classifications of a Fitzpatrick 3, Glogau 1, and Dedo 1 (Figure 3).



Figure 1: Photo demonstrating the patient in frontal repose.

Received date: 15 November 2020; **Accepted date:** 25 November 2020; **Published date:** 31 November 2020

Citation: Ivory JW, Jenzer AC, De Latour F (2020). Distraction Osteogenesis of the Mandible Followed by Lefort Osteotomy to Address Hemifacial Microsomia in an Adult Patient. SunText Rev Dental Sci 1(4): 120.

DOI: <https://doi.org/10.51737/2766-4996.2020.020>

Copyright: © 2020 Ivory JW, et al. This is an open-access article distributed under the terms of the Creative Commons Attribution License, which permits unrestricted use, distribution, and reproduction in any medium, provided the original author and source are credited.



Figure 2: Photo with patient in frontal animation. Note the significant cant.

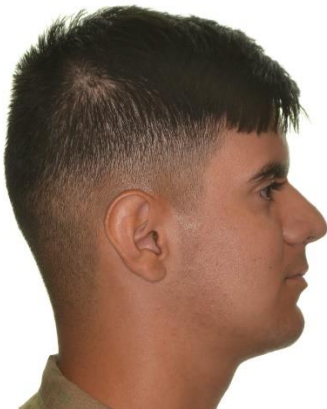

Figure 3: Patient in lateral profile.

Intra-orally, he was missing teeth 1,4,13,16,17,32, demonstrated a Class II molar – Class I canine relationship, and had good oral and periodontal hygiene (Figure 4).

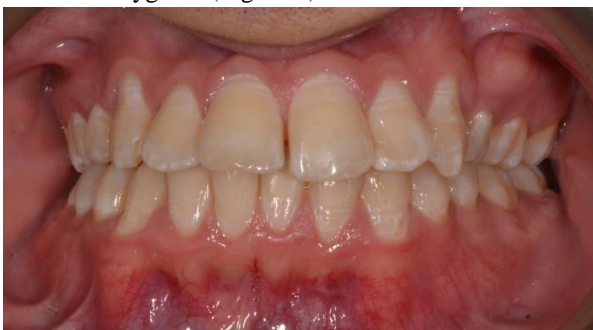

Figure 4: Intra-oral photo demonstrating centric occlusion.

His temporomandibular joints were unremarkable except for rare, minor, pain on the left side, later determined due to hyperfunction on that side because of his hypoplastic growth on the right. A

panoramic image and medical grade CT scan revealed a mandibular cant of 6mm (Figures 5 and 6). A scintigraphy scan was performed to rule out left condylar hypertrophy which was negative.

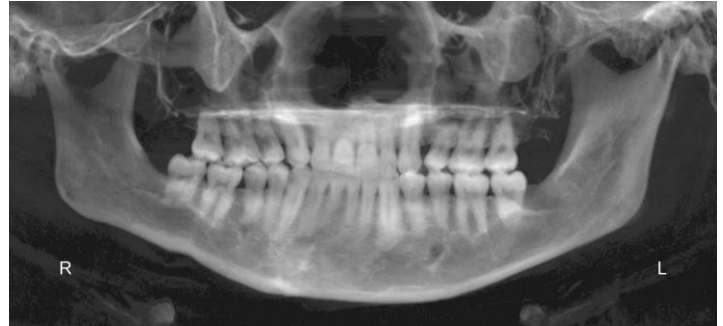

Figure 5: Reconstructed panoramic radiograph. Note mandibular asymmetry.

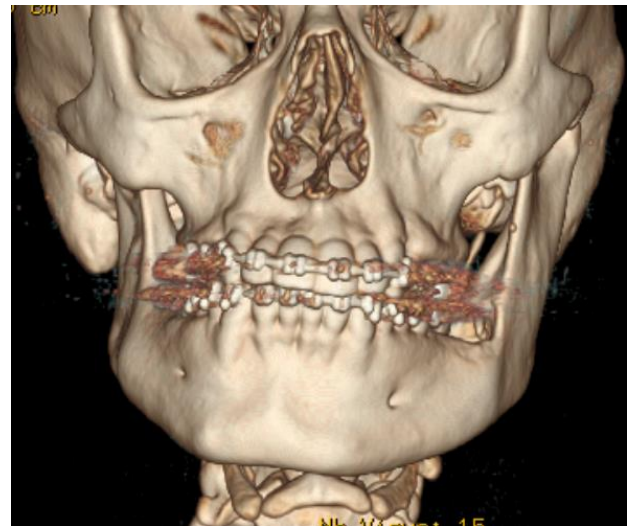


Figure 6: 3D CT reconstruction demonstrating significant deformity.

The patient was diagnosed with a dentofacial asymmetry secondary to right mandibular condylar and ramus hypoplasia. The case was presented to the local dentofacial deformity board and treatment plans created and reviewed with the patient to include doing nothing, orthognathic surgery with anticipated lefort I osteotomy and bilateral mandibular split osteotomies with a custom allograft implant to the left mandible with consideration for a genioplasty, distraction osteogenesis to the left mandible followed by orthognathic surgery, and a left sided custom temporomandibular joint replacement with a left single sided split osteotomy with lefort/genioplasty. After multiple treatment planning meetings with the patient and careful review of the risks and benefits and advantages and disadvantages of each option, the patient elected to proceed with the distraction osteogenesis option.

The surgery was then virtually planned by the team and a custom distractor and cut guides were fabricated (Figures 7- 9). The cut and distraction device were planned to maximize control of the vectors of force.

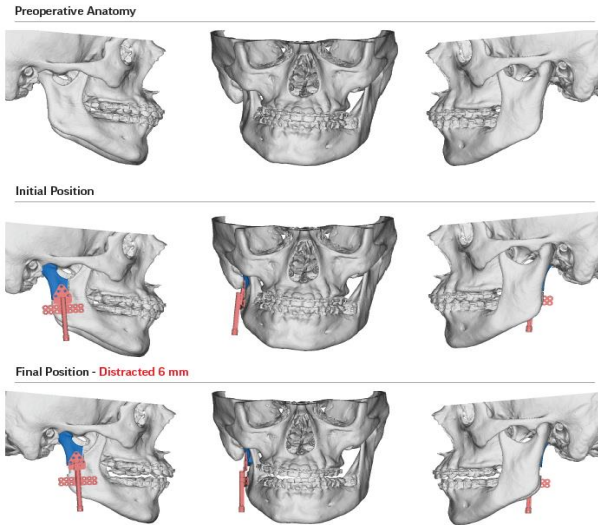


Figure 7: Pre-operative virtual surgical planning for custom distraction device.

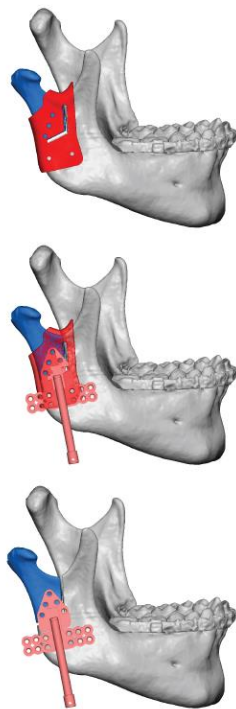


Figure 8: Pre-operative virtual surgical planning showing device and cut guide.

By creating an L shape and distracting in a vertical direction, the L shape ensured continued bony contact which would help maintain the vectors in the correct orientation.

In February of 2018 the patient was brought to the main operating room where, under general anesthesia, a retromandibular

approach was completed and the custom cut guide used to direct the precise cuts of the mandible with placement of the device (Figures 10-12).

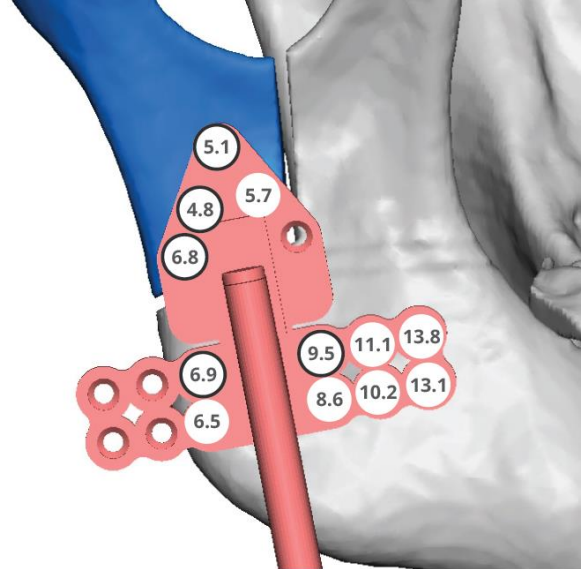


Figure 9: Pre-operative virtual surgical planning demonstrating screw depths.

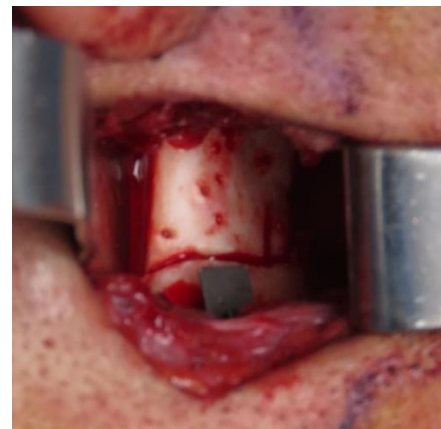

Figure 10: Intra-operative osteotomies completed using cut guide. Note additional corotomies completed to aid in maximizing blood flow to the area.

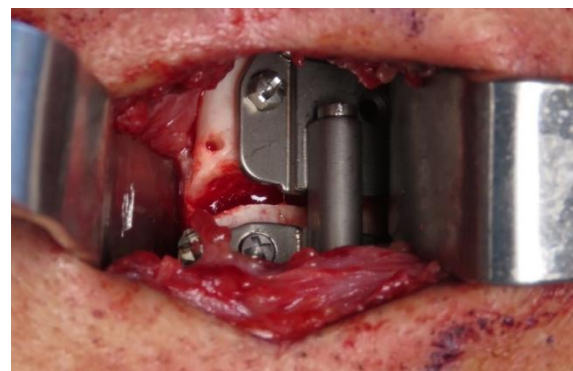


Figure 11: Intra-operative device placement.

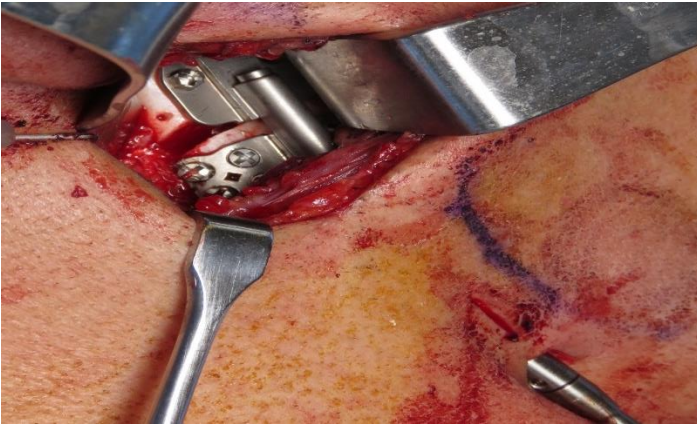


Figure 12: Intra-operative device placement posterior view.

The operation went smoothly with no complications or issues and the patient was discharged to home the next day. The device could rest passively for a latency period of seven days before an activation phase of nineteen days during which the mandible was distracted at a rate of 1.0-1.5mm per day. The distraction device was maxed out over the associated time period and then allowed to consolidate over twelve weeks. A CT scan was obtained at the end of this period demonstrating the gain from the device (Figures 13-16).

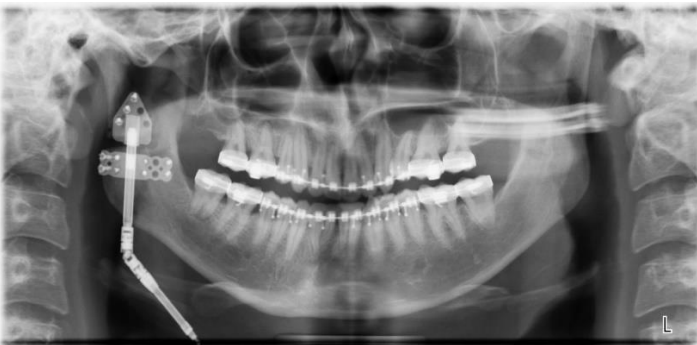

Figure 13: Post-distraction phase panoramic image with device in place.

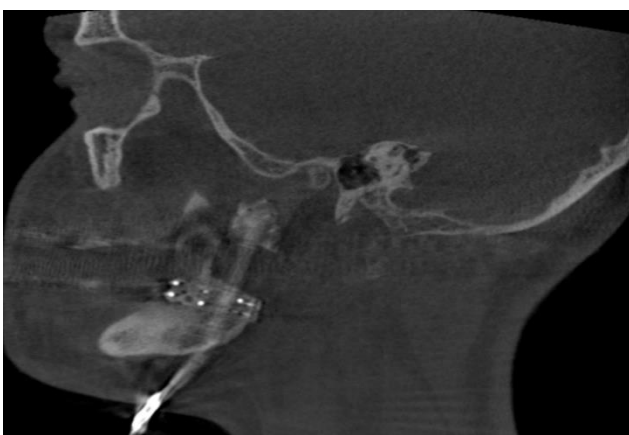

Figure 14: Post-distraction phase CT sagittal cut demonstrating distraction osteogenesis.

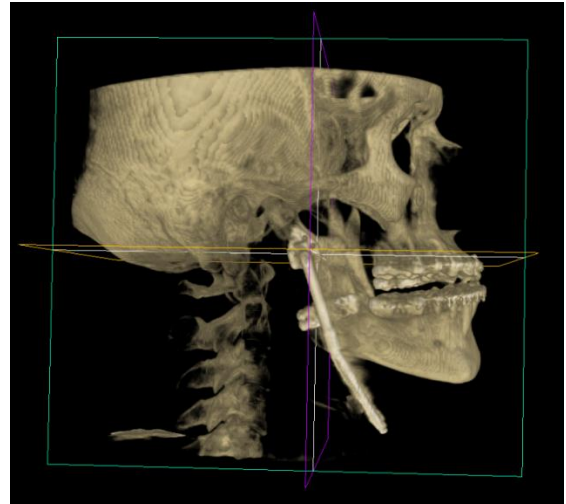


Figure 15: Post-operative 3D reconstruction showing vertical height gained from distraction.

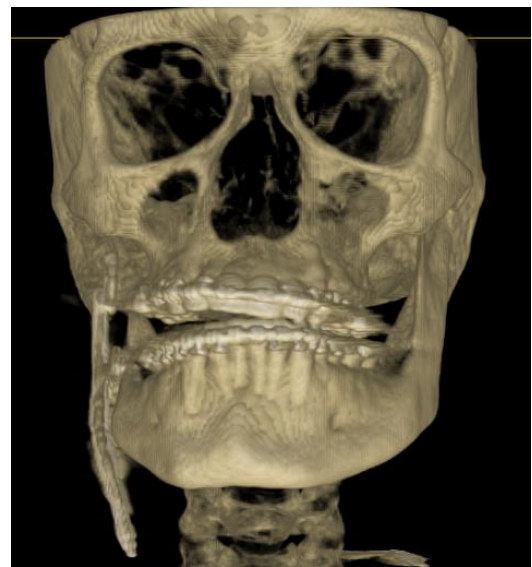


Figure 16: 3D reconstruction showing the change in occlusion on the left gained from the increase in vertical height from the distraction osteogenesis.

In March of 2018, the patient was brought back to the main operating room where he underwent removal of the distractor arm and placement of an occlusal splint without complications or issues. The final orthognathic surgical treatment plan was finalized as the distracted area continued to consolidate. The changes in the patient's appearance and occlusion were impressive already currently (Figures 17-19). The final plan was a lefort I osteotomy, genioplasty, and removal of the distraction device with placement of the custom plate for increased strength in the area, with associated three dimensional movements planned in the (Figures 20-22). The surgery was complete in the main operating room in June 2018 without complications or issues and

the patient was discharged to home the next day (Figures 23 and 24).



Figure 17a and 17b: Pre-op and post-distraction frontal repose.

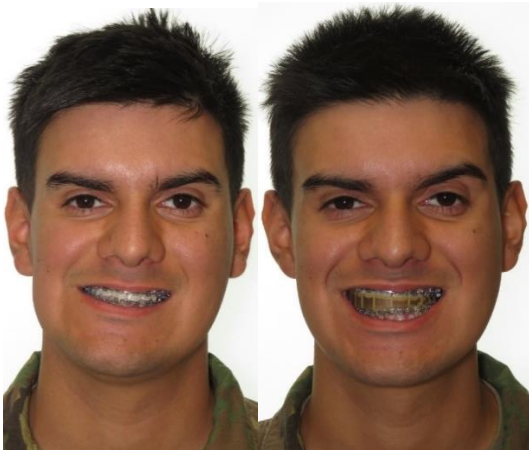


Figure 18a and 18b: Pre-op and post-distraction frontal animation.

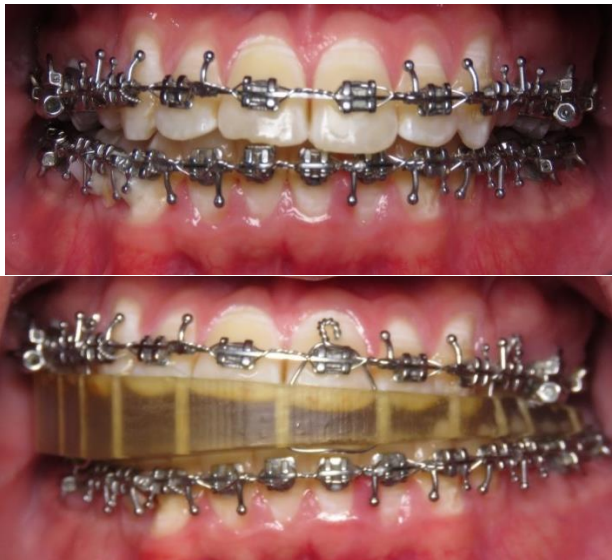

Figure 19a and 19b: Pre-op and post-distraction central occlusion.

Surgical Plan: Before and After

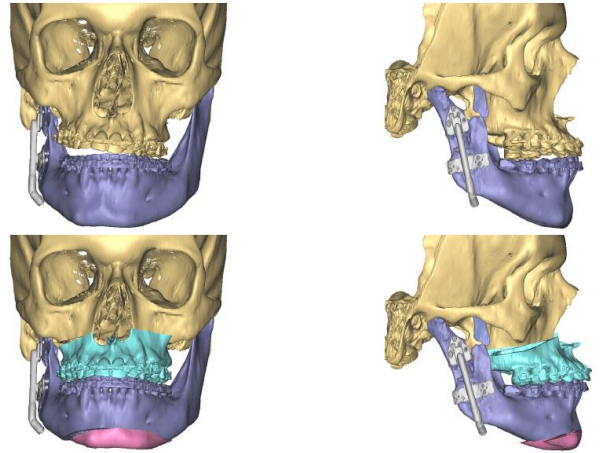


Figure 20: Pre-operative phase 2 virtual surgical planning for device removal and insertion of custom plate, Lefort 1 osteotomy, and genioplasty.

Surgical Plan: Cephalometric Analyses

The mandible measurements shown below are referenced from the original position of the mandible, at the time the CT was taken.

Point	Left/Right (mm)	Ant/Post (mm)	Up/Down (mm)
A	0.6 L	3.9 Ant	2.8 Up
ANS	0.0	3.5 Ant	3.0 Up
Maxilla Incisor Midline	2.4 L	5.3 Ant	3.4 Up
Maxilla Canine L	2.6 L	5.4 Ant	4.4 Up
Maxilla Canine R	2.3 L	5.2 Ant	0.5 Up
Maxilla 1st Molar L	2.6 L	5.4 Ant	4.0 Up
Maxilla 1st Molar R	2.2 L	5.1 Ant	1.4 Down
L Lateral Buttress	0.2 R	3.4 Ant	4.4 Up
L Medial Buttress	0.7 R	3.0 Ant	3.4 Up
R Lateral Buttress	0.2 L	3.6 Ant	2.6 Down
R Medial Buttress	0.6 R	3.1 Ant	0.9 Up
B	0.0	3.9 Ant	5.8 Up
Pog	9.0 L	5.0 Ant	6.0 Up
Me	8.2 L	5.9 Ant	5.7 Up
Mandible Incisor Midline	0.0	2.5 Ant	6.1 Up
Mandible Canine L	0.0	2.5 Ant	5.7 Up
Mandible Canine R	0.0	2.6 Ant	5.6 Up
Mandible 1st Molar L	0.0	2.8 Ant	4.3 Up
Mandible 1st Molar R	0.0	2.8 Ant	4.2 Up
Measurement (°)	Pre-Op 3D	Planned 3D	Delta 3D
SNA	85.9	90.6	4.7
SNB	85.6	88.5	2.9
ANB	0.9	2.7	1.8
Maxillary Occlusal Plane	5.6	2.6	-3

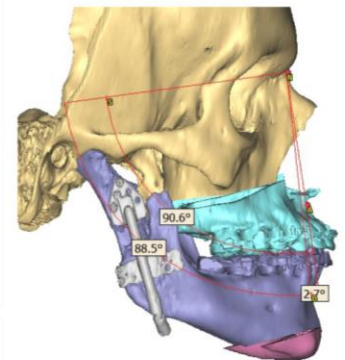


Figure 21: Pre-operative phase 2 virtual surgical planning for device removal and insertion of custom plate, Lefort 1 osteotomy, and genioplasty with cephalometric analysis.

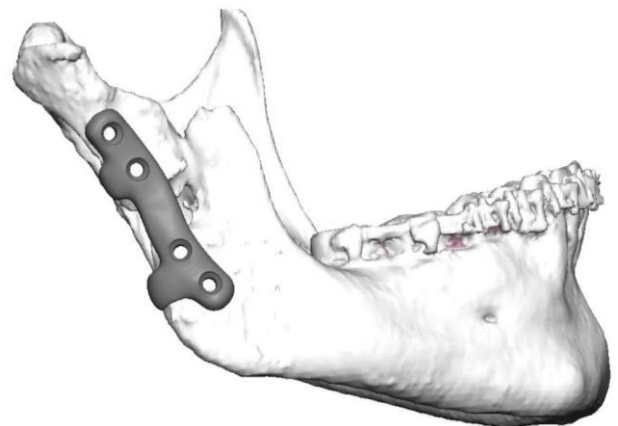


Figure 22: Custom plate to replace the device for increased strength to the area.

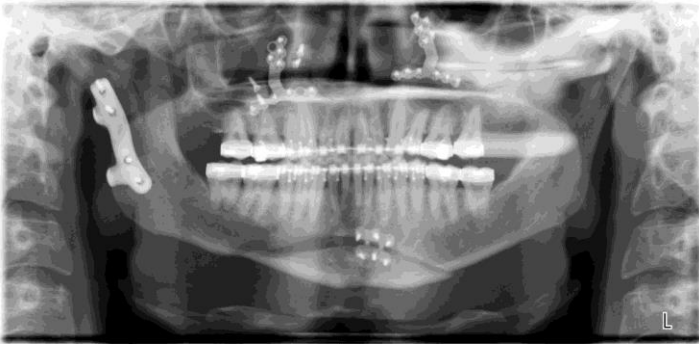


Figure 23: Post-operative panoramic image.



Figure 26: Post-operative final photo in frontal animation.

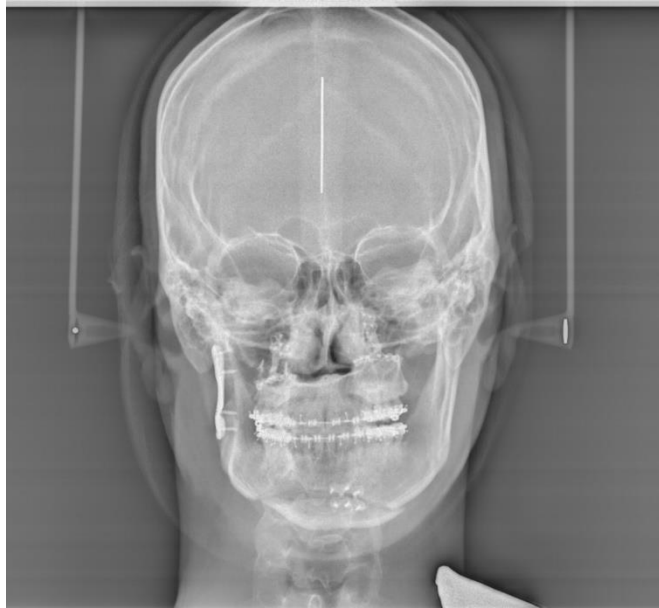

Figure 24: Post-operative AP cephalometric image.

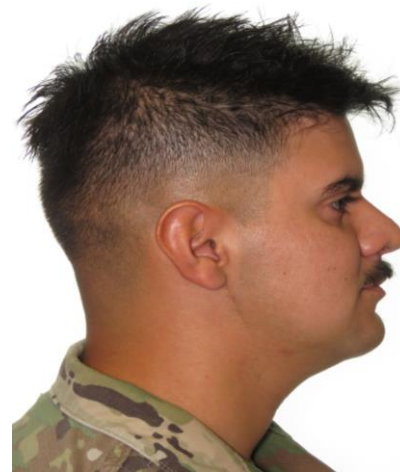

Figure 27: Post-operative final photo in lateral profile.



Figure 25: Post-operative final photo in frontal repose.

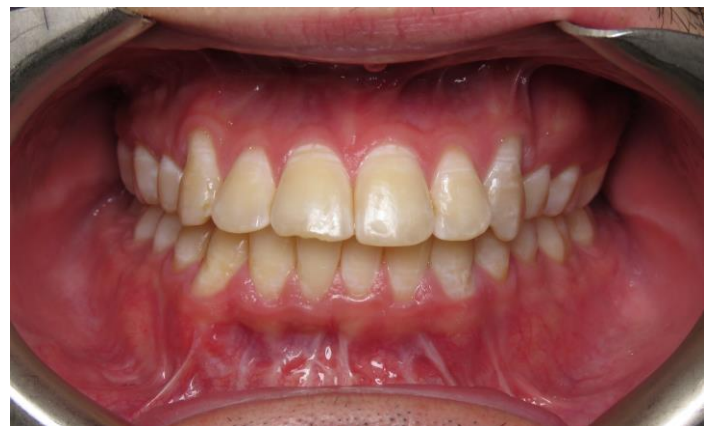

Figure 28: Post-operative final photo of central occlusion.

The patient then finished his orthodontic treatment and presented for interval exam with a final set of photos in May 2020 (Figures 25-28). The patient was satisfied with the outcome and had no complaints or issues.

Discussion

Distraction osteogenesis (DO) is a surgical technique that, while relatively new in its widespread use, has been around for over 100 years. The first reported case was an attempt by Alessandro Codivilla in 1905 to lengthen a femoral fracture [1]. In the early 1900s a number of cases were reported using DO to treat congenital craniofacial deformities [2-4]. From there, it gained popularity and increased use, surging with the publication by Ilizarov in the 1980's, which sparked deeper investigation and development [5]. In 1995, Klein et al published a study on distraction osteogenesis of nine cases of childhood unilateral and bilateral mandibular hypoplasia with a resulting average of lengthening of 21mm [6]. As the technology advanced to current day with custom devices and virtual planning, the significantly increased the control and predictability of the vectors involved and lead to better surgical outcomes. In the authors' opinions, it should be part of the armamentarium of any surgeon treating complex craniofacial deformities.

The biology involved in distraction osteogenesis is classically thought of in five distinct phases: osteotomy, latency, activation, consolidation, and re-modeling. The initial osteotomy is created with consideration for minimization of periosteal stripping and tissue reflection in order to best preserve the blood supply, designing surgery and approaches to minimize chance of contamination, particularly from intra-oral sources, and minimizing damage from heat and trauma to tissue and the surrounding area. A gap of 1-2mm is left open between the bony segments once the device is in place. This osteotomy gap, over approximately the next week, is the site of the most important part of the next phase, latency. The initial inflammatory response, with influx of cytokines, healing, and pro-inflammatory factors, sets the stage for the next phase, activation. Other techniques describe doing only a cortical osteotomy, which in turn requires a significantly larger distraction device to apply the necessary forces to distract bone. For that reason, this technique is not preferred in the head and neck region [7].

As the device is activated it is opened at a rate between 0.5mm to 1mm per day, divided into two to sessions. As the osteotomy gap progressively increases there is a reciprocal stretch and elongation of the collagen fibers within the gap. Mesenchymal cells at the periphery of the osteotomies move into the gap and undergo differentiation into a mix of cells including osteoblasts, fibroblasts, and chondroblasts [8]. Neovascularization concurrently takes place from the bony segments and periosteal walls. This milieu of collagen and healing factors within the distraction chamber allows for lengthening of the segment while maximizing blood and nutrient flow to the area. This new tissue forms parallel to the vector of traction [9].

The next phase is the consolidation portion, where this controlled injury is healed by the body. Mineralization begins at the bony walls and advances into the defect until the fibrous inter-zone is, hopefully, fully mineralized. Osteoid is deposited and woven bone formed with eventual re-modeling to lamellar bone. This time period is difficult to predict as one considers the factors involved; age, area, blood supply, systemic and/or local medical conditions, and the minutiae of bony healing that is yet to be fully elucidated especially in individual patients as it pertains to their genetics and immune systems. The last phase is re-modeling where the distractor is removed, and normal bony forces and tension allow shaping and continued transformation of the osseous tissue.

The key to successful distraction osteogenesis is the rate of distraction. During distraction, as the soft tissue surrounding the bone lengthens along with the bone. Soft tissue responds to tension through cellular proliferation [10]. A rate that is too slow can result in ossification of the osteotomy, requiring a second surgery. A rate that is too fast will not allow soft tissues to proliferate and will likely compromise vascular supply to the surgical site.

Distraction osteogenesis is a therapy that has a wide range of applications within the scope of head and neck surgeons. Treatment of congenital syndromes, to include conditions such as hemifacial macrosomia and Pierre Robin Syndrome to name a few, is a prime population where this therapy shines, especially in pediatric patients [11-14]. Augmentation of alveolar bone in the gnathic bones, particularly for the often difficult to attain vertical ridge augmentation, is another application where distraction osteogenesis offers a useful therapy [15].

However, one must weigh the relative advantages and disadvantages of using this technique against the unique problem set of each case. The major advantage in distraction osteogenesis is that often allows for greater movements of bone when compared to an osteotomy alone. It brings along soft tissue and vascular supply generally resulting in greater soft tissue and bone bulk [16]. The resulting bone is already fully vascularized and can preclude the need for further augmentation surgeries. Specific for cases such as described above, treatment of hemifacial microsomia, often greater symmetry can be achieved as compared to orthognathic surgery alone, since as the mandibular ramus is lengthened, it results in a more balanced symmetry at the gonial angles, avoiding the need for a later implant at the aforementioned site. With virtual surgical planning and custom devices fabricated to the patient and the plan, the surgeon can control all aspects of the case, from osteotomy and placement in order to avoid vital structures like the inferior alveolar nerve, tooth roots, etc., while maximizing control of the vectors to increase predictability of a favorable result.

There are, of course, disadvantages as well. The discomfort and social stigma associated with having the device protruding through the skin, if an external device is used, combined with the longer length of time, and most commonly, a second procedure to remove the device as well as any subsequent surgeries, are all relative disadvantages. Facial scarring can occur secondary to the surgical approaches and the protruding device. Patient acceptance and buy-in, for these reasons, can be difficult. Relapse is another potential issue that many studies have looked at, for example Strijen et al. showed that in fifty patients, high angle patients have a significantly higher relapse than low angle patients [17].

Some of these relative disadvantages can be mitigated by considering vectors. The vector is based on the mandibular shape and the desired end goal [18]. Treating a multi-vector case with a single vector device has been a studied source of criticism and debate. However, Singh demonstrated that this can be overcome with careful preoperative planning [19]. Internal vector control and distraction is possible with newer devices and remains an interesting area of future exploration and is definitely a viable option of exploration depending on the patient and based on the specifics of the case.

Overall, distraction osteogenesis is an excellent therapy that should be part of any head and neck surgeon's armamentarium of treatment modalities.

References

1. Codivilla A. On the means of lengthening in the lower limbs, the muscles and tissues which are shortened through deformity. *Am J Orthop Surg.* 1905; 2: 353-363.
2. McCarthy JG, Schreiber J, Karp N. Lengthening the human mandible by gradual distraction. *Plast Reconstr Surg.* 1992; 89: 1-8.
3. McCormick SU, McCarthy JG, Grayson BH. Effect of mandibular distraction on the temporomandibular joint. Part I. *J Craniofac Surg.* 1995; 6: 358-363.
4. Rosenthal W. Kiefergelenksankylose und Mikrogenie. *Dtsch Zahnarztl Z.* 1949; 4: 786-793.
5. Ilizarov GA. The principle of the Ilizarov method. *Bull Hosp Joint Dis.* 1988; 48: 1-11.
6. Klein C, Howaldt HP. Lengthening of the hypoplastic mandible by gradual distraction in childhood--a preliminary report. *J Craniofac Surg.* 1995; 23: 68-74.
7. Kubler AC, Zoller JE. Facial distraction techniques in maxillofacial trauma and esthetic facial reconstruction. 2012; 470.
8. White SH, Kenwright J. The importance of delay in distraction of osteotomies. *Orthop Clin North Am.* 1991; 22: 569-579.
9. Bagheri S, Bell RB, Khan H. Guerrero current therapy in oral and maxillofacial surgery; principles of distraction osteogenesis. Elsevier, St. Louis, MI; 2012; 11: 101-111.
10. Ippolito E, Peretti G, Bellocchi M. Histology and ultrastructure of arteries, veins, and peripheral nerves during limb lengthening. *Clin Orthop Relat Res.* 1994; 308: 54-62.
11. Polley JW, Figueroa AA. Distraction osteogenesis: its application in severe mandibular deformities in hemifacial microsomia. *J Craniofac Surg.* 8: 422-430.
12. Wiens JL, Forte RA, Wiens JP. The use of distraction osteogenesis to treat hemifacial microsomia: A Clinical Report. *J Prosthet Dent.* 2003; 89.
13. Rachmiel A, Manor R, Peled M, Laufer D. Intraoral distraction osteogenesis of the mandible in hemifacial microsomia. *J Oral Maxillofac Surg.* 59: 728-733.
14. Bangeyev JV, Traboulsi H, Abdulhamid I, Rozelle A, Thottam PJ. Sleep architecture in Pierre-Robin sequence: The effect of mandibular distraction osteogenesis. *Int J Pediatric Otorhinolaryngol.* 2016; 89: 72-75.
15. Adolphs N. Stable vertical distraction osteogenesis of highly atrophic mandibles after ablative tumour surgery of the oral cavity – a salvage pathway for mandibular reconstruction prior to oral rehabilitation with dental implants. *J Craniofac Surg.* 2009; 37: 320-326.
16. McCarthy JG. The role of distraction osteogenesis in the reconstruction of the mandible in unilateral craniofacial microsomia. *Clin Plast Surg.* 1994; 21: 625-631.
17. Van Strijen PJ, Breuning KH, Becking AG, Tuinzing DB. Stability after distraction osteogenesis to lengthen the mandible: results in 50 patients. *J Oral Maxillofac Surg.* 2004; 62: 304-307.
18. Grayson BH, McCormick S, Santiago PE, McCarthy JG. Vector of device placement and trajectory of mandibular distraction. *J Craniofac Surg.* 1997; 8: 473-480.
19. Singh DJ, Glick PH, Bartlett SP. Mandibular deformities: single-vector distraction techniques for a multivector problem. *J Craniofac Surg.* 2009; 20: 1468-1472.