



Congenital Diaphragmatic Hernia in Eight Month Old Girl – An Incidental Diagnosis

Patra S^{1*} and Patra SK²

¹Department of Pediatrics, LLH Hospital, Musaffah, Abu Dhabi, UAE

²Department of ENT, LLH Hospital, Musaffah, Abu Dhabi, UAE

*Corresponding author: Patra S, Department of Pediatrics, LLH Hospital, Musaffah, Abu Dhabi, UAE; E-mail: drsridevigandham@gmail.com

Abstract

Congenital diaphragmatic hernia (CDH) is a congenital defect in the diaphragm that occurs during embryogenesis. It allows herniation of abdominal contents like stomach, intestines, liver, gallbladder, pancreas and spleen into the thoracic cavity leads to varying degrees of pulmonary hypoplasia and pulmonary hypertension. CDH occurs in 1 in 3,000 births and can range from mild to severe. Advances in prenatal diagnosis and the institution of standardized delivery and postnatal care protocols have led to improved survival. Most cases of CDH usually effectively managed postnatally. Advances in neonatal and surgical care have resulted in improved outcomes over the years. When available, extracorporeal membrane oxygenation can provide temporary cardiorespiratory support for those not effectively supported by mechanical ventilation. In spite of these advances, very severe cases of CDH still carry a very high mortality and morbidity rate. Advances in imaging and evaluation now allow for early and accurate prenatal diagnosis of CDH, thereby identifying those at greatest risk and may benefit from prenatal intervention. This case diagnosed incidentally on radiology while treating for acute pneumonia.

Keywords: Congenital diaphragmatic hernia (CDH)

Introduction

Diaphragmatic hernias occurs due to weakness, or opening, in the diaphragmatic muscles present below the lungs, which separates the thoracic cavity and abdominal cavity. Abdominal organs such as the stomach, intestines, spleen, or liver can herniate through the opening and appear in the thoracic cavity compromising thoracic organs, which can be a surgical emergency. CDH is twice more common in female than males. Defects are more common in left side (85%) cases and occasionally bilateral. Most cases are sporadic but familial cases also reported. It can be associated with CNS abnormalities, esophageal atresia cardiovascular abnormalities and omphalocele. Many cases diagnosed antenatally by prenatal ultrasound at 16 to 24 week. Postnatally a chest X-ray helps in diagnosis. In some children echogenic chest mass needs further imaging.

Case Report

An eight -month-old female child referred from clinic with history of fever, running nose and cough for 10 days, not responding to oral antibiotics. Her vital signs at admission were temperature of 38.7c, heart rate 144/minute, Respiration rate 44/minute, oxygen saturation 95%. On physical examination, child looking tired. Chest had rhonchi and crepitations. All routine blood investigations were done. Chest X ray was showing prominent Broncho vascular markings with faint patchy opacities on both lung fields- suggestive of pneumonitis. A well-defined rounded opacity of approximate size 4.2* 3.7cm was notes in region of right cardio phrenic angle, mostly hiatal hernia or posterior mediastinal lesion. For confirmation Computerized Tomography of abdomen done, which was showing right sided diaphragmatic hernia on posterior aspect with liver herniating in to thorax with collapse consolidation of underlying lower lobe of right lung. There were patchy consolidation upper and lower lobes of left lungs. Pulmonary AV malformation in lower lobe of right lung as there was a tortuous vascular channel noted from the descending branch of right pulmonary artery noted draining into

Received date: 23 August 2023; **Accepted date:** 29 August 2023; **Published date:** 04 September 2023

Citation: Patra S, Patra S (2023) Congenital Diaphragmatic Hernia in Eight Month Old Girl – An Incidental Diagnosis. SunText Rev Case Rep Image 4(6): 200.

DOI: <https://doi.org/10.51737/2766-4589.2023.100>

Copyright: © 2023 Patra S, et al. This is an open-access article distributed under the terms of the Creative Commons Attribution License, which permits unrestricted use, distribution, and reproduction in any medium, provided the original author and source are credited.

the right inferior pulmonary vein. Kinking of the IVC noted at the diaphragm. She was treated with the IV antibiotics, other conservative treatment and discharged. She was referred to Pediatric surgeon, who advised for surgery. Child underwent elective surgery in India. She is in regular follow up in outpatient department without any complications with normal physical growth (Figure 1).

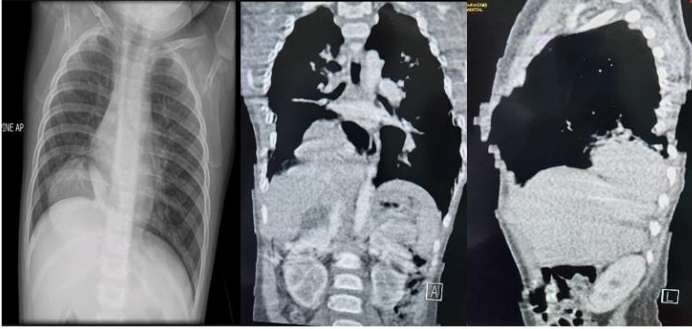


Figure 1: Chest X ray and CECT abdomen scan.

Discussion

The present case highlights an asymptomatic case of a Congenital Diaphragmatic hernia, diagnosed accidentally while under treatment for acute pneumonia. Congenital diaphragmatic hernia affects approximately 1 in 3,000 newborns [1]. CDH is a defect in the muscles and other fibrous tissues of the diaphragm, which separates the organs in the abdomen from those in the chest. An absent or partially formed diaphragm leads to an abnormal opening (hernia) that allows the stomach, intestines, liver, and other abdominal organs to move into the chest cavity causing lung hypoplasia. It results in life-threatening respiratory distress apparent after birth. CDH is one of the most severe birth defects, with extremely high neonatal mortality. Diaphragmatic hernias are common. Even if frequently incidental, recognition of both benign and life-threatening features of diaphragmatic hernias is required to plan appropriate treatment [2]. Antenatal ultrasound screening and if needed use of magnetic resonance imaging is helpful in diagnosis. After birth, immediate intubation and gentle ventilation are important in life-threatening symptomatic cases. Pulmonary hypertension is common and its optimal management is important as its severity predicts the outcome. Usually, surgery delayed until the baby is optimally stabilized [3]. In some cases, a prenatal procedure improves the possibility of neonatal survival [4]. Survivors may have long-term morbidities, like pulmonary dysfunction, gastroesophageal reflux, musculoskeletal deformities, and neurodevelopmental impairment [5]. Late-onset CDH can present with respiratory or gastrointestinal symptoms. Gastrointestinal symptoms are more common in left-sided hernias, whereas right-sided lesions present with predominantly respiratory symptoms. The prognosis is excellent once the correct

diagnosis is made and correction done [6]. The absence of typical clinical presentation in cases of late presenting CDH leads to delayed diagnosis of CDH. CDH should be taken into account in the differential diagnosis of children with respiratory distress and GI disturbances. Imaging studies needed for diagnosis [7]. We here report the case of an eight-month-old girl with a right diaphragmatic hernia presenting with breathing difficulty, cough, and acute pneumonia. Chest X-ray and computed tomography scan reported right CDH on the posterior aspect with liver herniating in the thorax with collapse consolidation of the underlying lower lobe of the right lungs. The defect corrected through open surgical repair without complication [8]. A radiograph was performed at the 10-month follow-up, which revealed full recovery. This report alerts physicians to suspect this diagnosis in patients with rare presentations of diaphragmatic hernia.

Conclusion

- This report demonstrates a case of an asymptomatic right diaphragmatic hernia.
- Although most of the cases are diagnosed antenatally, few children present late.
- Suspect this diagnosis in patients with rare presentations of diaphragmatic hernia.

Additional information

Author contributions: SP and SKP have contributed equally in writing and reviewing of the manuscript. SP is the article guarantor.

References

1. Wilson JM, Lund DP, Lillehei CW, Vacanti JP. Congenital diaphragmatic hernia - a tale of two cities: the Boston experience. *J Pediatr Surg.* 1997; 32: 401-405.
2. Sandstrom CK, Stern EJ. Diaphragmatic hernias: a spectrum of radiographic appearances. *Current problems in diagnostic radiology.* *Curr Probl Diagn Radiol.* 2011; 40: 95-115.
3. Kotecha S, Barbato A, Bush A, Claus F, Davenport M, Delacourt C, et al. Congenital diaphragmatic hernia. *Eur Respir J.* 2012; 2012: 820-829.
4. Kosiński P, Wielgoś M. Congenital diaphragmatic hernia: pathogenesis, prenatal diagnosis and management—literature review. *Ginekologia polska.* 2017; 88: 24-30.
5. Zani A, Chung WK, Deprest J, Harting MT, Jancelewicz T, Kunisaki SM, et al. Congenital diaphragmatic hernia. *Nat Rev Dis Primers.* 2022; 8: 37.
6. Kitano Y, Lally KP, Pamela A. Late-presenting congenital diaphragmatic hernia. *J Pediatr Surg.* 2005; 40: 1839-1843.
7. Zaleska-Dorobisz U, Bałaj M, Sokołowska D, Ładogórska J, Moroń K. Late presenting diaphragmatic hernia: clinical and diagnostic aspects. *Medical Science Monitor.* 2007; 13: 137-146.



8. Ghabisha S, Ahmed F, Al-Wageeh S, Al-Shami E, Al-Hajri A, Aljbri W, et al. Delayed presentation of congenital diaphragmatic hernia: a case report. *Pan Afr Med J.* 2021; 40.