



A Rare Cause of Recurrent Haemoptysis in an Adult Woman: A Case Report

Tan C¹ and Kumar P^{2,*}

¹6th year MBBS James cook university, Australia

²FRACP, Respiratory Physician, Mackay Base Hospital, Australia

*Corresponding author: Kumar P, Respiratory Physician, Mackay Base Hospital, 475 Bridge Road, Mackay, Queensland, Australia

Received date: 24 December 2023; Accepted date: 28 December 2023; Published date: 31 December 2023

Citation: Tan C, Kumar P (2024) A Rare Cause of Recurrent Haemoptysis in an Adult Woman: A Case Report. SunText Rev Case Rep Image 5(1): 117.

DOI: <https://doi.org/10.51737/2766-4589.2024.117>

Copyright: © 2024 Tan C, et al. This is an open-access article distributed under the terms of the Creative Commons Attribution License, which permits unrestricted use, distribution, and reproduction in any medium, provided the original author and source are credited.

Abstract

A rare congenital malformation of the respiratory tract, bronchopulmonary sequestration, may present symptomatically early on in childhood or adolescent years. Adult bronchopulmonary sequestration is typically an incidental finding found on thoracic imaging. There is currently 4 known types of bronchopulmonary sequestration. Intralobar sequestrations are the most common of them. Extralobar sequestration is totally separate from the lung and has a distinct pleural covering. Extralobar sequestration has no communication with the airway, and the chance of it becoming symptomatic in adults is very small. We present herein a case of extralobar sequestration that caused hemoptysis.

Keywords: Adult bronchopulmonary sequestration; Intralobar; Extralobar

Introduction

Bronchopulmonary sequestration (BPS), simply known as pulmonary sequestration, is a rare type of congenital lung malformation of the lower airway. Whereby a non-functional mass of lung parenchyma is present but lacks a tracheobronchial connection to the rest of the functioning airway. This mass then receives its arterial blood supply through the systemic circulation [1]. Currently, BPS accounts for approximately 3% of all congenital lung malformations. Congenital lung malformation account for approximately 10% of all congenital anomalies, while BPS accounts for just 1-3% of all congenital lung malformations [2]. This case report describes this rare condition in a 56-year-old healthy female which manifested initially as haemoptysis.

Case Report

A 56-year-old woman was referred to the respiratory clinic after a CT scan showed an incidental finding of a possible BPS. The CT scan was initially done due to multiple episodes of haemoptysis, however when she was reviewed in the clinic, she was largely asymptomatic except for notable exertional dyspnoea. Just prior to the referral to the respiratory clinic, she was seeing a cardiologist who have worked up and determine there to be no

cardiac cause of her exertional dyspnoea. She is otherwise well, generally healthy and has no constitutional symptoms. She has completely recovered from a recent episode of pneumonia which was managed entirely with oral antibiotics. Her medical history is notable for hypothyroidism of which she is on daily oral Thyroxine for. She also takes estrogen for her menopausal symptoms. She is not aware of any known birth defects. She has worked in an office environment as a receptionist for 40 years. Her family history was unremarkable. She was a previous smoker with a 15 pack years. On examination, she is of a lean body habitus, does not use any accessory oxygenation devices or puffers. She was afebrile, had a respiratory rate of 12, and her oxygen saturations were 98% at room air. There was no evidence of respiratory distress or chronic hypoxemic states. There was no clubbing or appreciable cervical or axillary lymphadenopathy. There was a dull percussion note with mildly decrease air entry on her left middle to lower zone. The rest of her systems examination was unremarkable.

Bloodwork done for her showed a mild normocytic anaemia but was confirmed to be at baseline when looking at previous blood results. Her kidney, liver and thyroid functions were unremarkable. Her C reactive protein (CRP) and erythrocyte

sedimentation rate (ESR) was within normal limits. Autoimmune screening was negative and complement levels were normal. A full lung function test done essentially showed normal respiratory function, with normal spirometry, lung volumes and diffusion capacity.

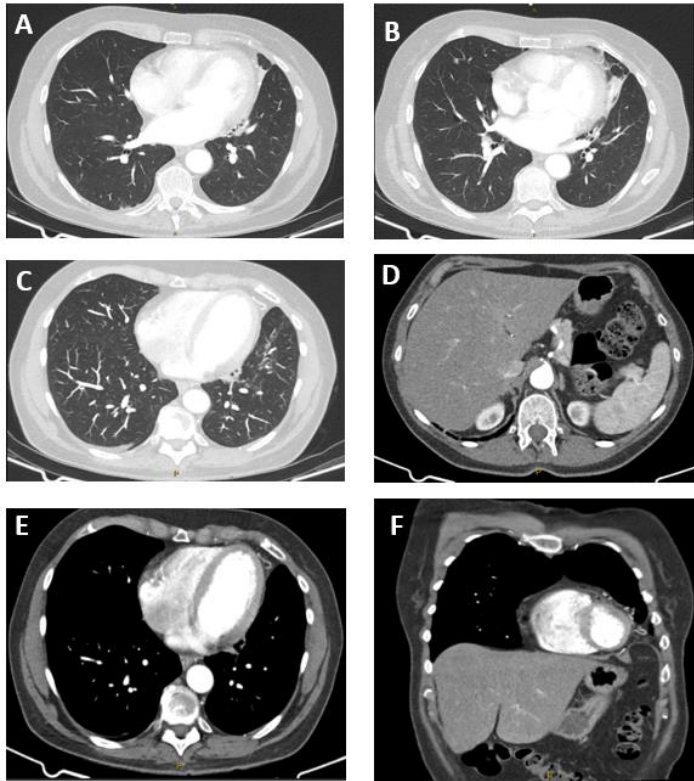


Figure 1: CT scan findings. A-C: Different slices showing the “triangular density” as an inferior lingula sequestration. D: Arterial phase image showing celiac trunk as origin of the aberrant blood supply. E-F: Arterial phase images showing the arterial supply into the lobar sequestration.

A repeat CT scan, once again showed a similar collapsed/fibrotic “triangular density” segment in the level of the inferior lingula with evidence of an aberrant systemic arterial supply as shown in (Figure 1). Based on the CT scan, the probable diagnosis of BPS was given. However, the contradicting radiological finding was a possible tracheobronchial connection, and the recommendation for a diagnostic bronchoscopy was given.

Thoracic aortogram done showed a hypertrophied branch of the left internal mammary artery (internal thoracic artery) and a serpiginous artery arising from the celiac trunk of the infra-diaphragmatic segment of the aorta. Once arising from the celiac trunk, the serpiginous artery enters the aortic hiatus of the diaphragm, over the dorsal surface of the diaphragm, and courses lateral to the cardiac apex to supply the pathological inferior lingula segment of interest. A diagnostic bronchoscopy carried out showed no tracheobronchial connection and an anatomic narrowing of the lumen at the inferior lingula, as shown in (Figure

2). Washings done acquired a blood tinged fluid from the lingula segment of the left lung, and the rest of cultures, acid fast bacilli, and cytology were unremarkable. As a result of the above findings, the diagnosis of extralobar sequestration, a type of BPS, was given.

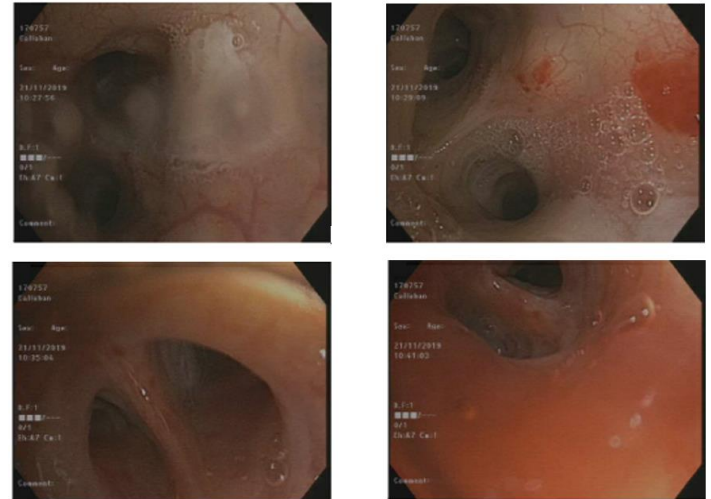


Figure 2: Bronchoscopy images of left upper lobe showing no tracheobronchial connection of the extralobar sequestration.

Discussion

There are currently 4 known types of BPS. Intralobar sequestration (ILS), the most common type, is characterized by the sequestered lobe being present within the normal lobe and lacking its own visceral pleura. Extralobar sequestration (ELS), is where the sequestered lobe is found outside the normal lobes of the lung and has its own visceral pleura. There are other forms of ELS, such as extrathoracic ELS. Congenital pulmonary airway malformation (CPAM), also known as hybrid BPS, is where the malformed lesion is either an ILS or ELS and possessing unique histological CPAM features. Lastly, bronchopulmonary foregut malformation is where the sequestered lobe is abnormally connected to the gastrointestinal tract, which happens during the development of the foregut, hence its name [1,3-5]. ILS accounts for about 75% of BPS, while ELS accounts for 25% of BPS [1,3]. The pathogenesis of BPS, though not completely understood, has an embryological basis to many theories [2]. The clinical presentation differs in the based on the type of BPS. Half of all adults with ILS are asymptomatic. BPS are often discovered as an incidental finding. If symptomatic, ILS commonly presents as recurrent pneumonias due to the absence of the visceral lining. Conversely, ELS do not present with infections, but with rare complications such as respiratory distress, congestive cardiac failure or spontaneous pulmonary haemorrhages. In this instance, the cause of the episodic haemoptysis may be due to the high pressure blood flow coming through the abnormal serpiginous



artery from the abdominal aorta during high physiological demand states e.g. stress or exercising [1].

Imaging modalities used help to attain 2 main objectives. First to exclude other possible causes and second to demonstrate an arterial supply from a systemic source [1,4]. On CT scan, the sequestered lung mass may often present radiologically as a cyst secondary to recurrent infections, dense mass, lamellar lesion, capsulated lesion with air fluid levels, atelectatic or bronchiectatic segments [2,4]. Accompanying emphysema are sometimes found adjacent to the sequestered lung [4]. A step further to acquire three dimensional reconstructions from the CT scans are often helpful. Imaging is often sufficient to make the diagnosis of BPS. Our patient required a diagnostic bronchoscopy to further ascertain if there was a tracheobronchial connection.

The management option for BPS is surgical resections, that can be done either via thoracostomy or video-assisted thoracoscopic surgery however it's typically reserved for symptomatic patients. A recent tertiary centre retrospective study done showed a complication rate of 28% [3]. While another study showed no clear benefit of surgery in asymptomatic patients [6]. Hence, the decision to surgically resect the sequestered lobe should come down to the analysis of the risks and benefits. Interestingly, with the rise of interventional radiology, endovascular embolization and coiling have now emerged as possible alternatives, by means of cutting off blood supply to the sequestered lung leading to necrosis and resultant involution [1,6].

Conclusion

In summary, we present a rare cause of haemoptysis due to an extralobar pulmonary sequestration, found through an incidental finding in an adult female who have been relatively asymptomatic all her life up till this point. This extralobar sequestration was rare because of its connection to normal lung. It is difficult to determine whether the connection between the sequestered lung and the left lower lobe was congenital or acquired as a result of an inflammatory process. However, we suspect that the connection was congenital. A familiarity of aspects of this rare disease should prompt one to consider its' diagnosis when no other causes are apparent. A combined decision by the clinician and radiologist is usually required to make the diagnosis. The treatment decisions of BPS should be done coordinatively with multidisciplinary team members, the patient, and their families.

References

1. Chakraborty RK, Modi P, Sharma S. Pulmonary Sequestration. StatPearls. StatPearls Publishing.
2. Halkic N, Cuénoud PF, Corthésy ME, Ksontini R, Boumghar M. Pulmonary sequestration: a review of 26 cases. *Euro J Cardio-Thoracic Surg.* 1998; 14: 127-133.

3. Sun X, Xiao Y. Pulmonary sequestration in adult patients: a retrospective study. *Eur J Cardiothorac Surg.* 2015; 48: 279-282.
4. Abbey P, Das C, Pangtey G, Seith A, Dutta R, Kumar A. Imaging in bronchopulmonary sequestration. *J Medical Imaging Radiation Oncol.* 2009; 53: 22-31.
5. Cass DL, Crombleholme TM, Howell LJ, Stafford PW, Ruchelli ED, Adzick NS. Cystic lung lesions with systemic arterial blood supply: a hybrid of congenital cystic adenomatoid malformation and bronchopulmonary sequestration. *J Pediatr Surg.* 1997; 32: 986-990.
6. Alsumrain M, Ryu JH. Pulmonary sequestration in adults: a retrospective review of resected and unresected cases. *BMC Pulm Med.* 2018; 18: 97.